

Case Report

Infantile Refsum Disease With Enamel Defects: A Case Report

Dorothy Tran, DDS¹ • William Greenhill, DMD² • Stephen Wilson, DMD, MA, PhD³

Abstract: The purpose of this paper was to present the case of a 15-year-old female diagnosed with infantile Refsum disease (IRD) that presented with generalized enamel defects in the primary and permanent dentition. IRD is an inherited autosomal recessive disorder characterized by aberrant peroxisome function. IRD patients present with multiple clinical manifestations, including: retinitis pigmentosa; nystagmus; sensorineural hearing loss; mental and developmental delays; neuromotor defects; and cerebral ataxia. Craniofacial abnormalities reported include: high forehead; hypoplastic supraorbital ridges; epicanthal folds; midface hypoplasia; and large anterior fontanelle. At present, there is only one known report of dental anomaly associated with this syndrome. This represents the first known reported case in the pediatric dental literature. (*Pediatr Dent* 2011;33:270-4) Received November 5, 2009 | Last Revision April 8, 2010 | Accepted April 8, 2010

KEYWORDS: CHILDREN WITH SPECIAL HEALTH CARE NEEDS, GENETICS, SYNDROMOLOGY / CRANIOFACIAL ANOMALIES

Infantile Refsum disease (IRD) is inherited in an autosomal recessive manner, and the incidence is unclear. An estimate of 1 in 25,000 and 1 in 50,000 is reported for the total of all leukodystrophy disorders in which there is overlap of IRD with other diseases. Leukodystrophy disorders are a group of genetic disorders that result in the progressive degeneration of white matter in the brain due to imperfect growth or formation of myelin surrounding the nerves.¹ IRD has been associated with parental consanguinity and is an inherited disorder specifically characterized by aberrant peroxisome function.²

IRD also falls within a spectrum of diseases known as peroxisome biogenesis disorders, (PBDs) which is a subgroup of the leukodystrophies. PBDs include IRD, Zellweger syndrome (ZS), neonatal adrenoleukodystrophy (NALDS), and rhizomelic chondrodysplasia.³ IRD, ZS, and NALDS are distinct from rhizomelic chondrodysplasia and are usually referred to as the Zellweger spectrum.⁴ IRD has similar clinical presentation to other disorders in this class of disease; however, it is considered to be the mildest form of the PBDs.⁵

The pathophysiology of this disorder is characterized by abnormal cellular function, specifically within the peroxisome. Peroxisomes are ubiquitous organelles of eukaryotic cells that contain enzymes responsible for many metabolic pathways, mainly the metabolism of lipids and fatty acids, including phytanic acid.⁶ In syndromes such as IRD in which

peroxisome function is compromised, it is clear that these organelles play an important role in cellular metabolism. Their lack of function in IRD results in an accumulation of phytanic acid in the blood and tissues, including fat and neurons.²

The clinical manifestations of IRD result from this disruption in the development of neural components, resulting in defects in systems that rely on neuronal transmission. Signs and symptoms common in IRD patients appear with varying degrees of impaired vision, including: retinitis pigmentosa and nystagmus; sensorineural hearing loss; mental and developmental delays; and, due to high concentrations of protein

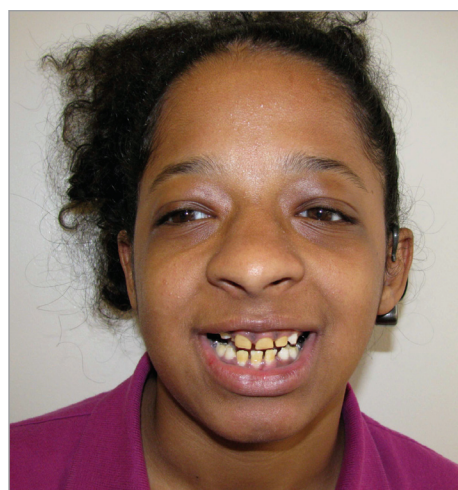

Figure 1. Frontal view demonstrating high forehead, low-set ears, hypoplastic supraorbital ridges, epicanthal folds, midface hypoplasia, hypertelorism, and broad nasal bridge.

¹Dr. Tran is second-year resident, ²Dr. Greenhill is assistant professor, and ³Dr. Wilson is professor and chair, all in the Division of Pediatric Dentistry, Cincinnati Children's Hospital Medical Center, Cincinnati, Ohio.

Correspond with Dr. Greenhill at william.greenhill@cchmc.org

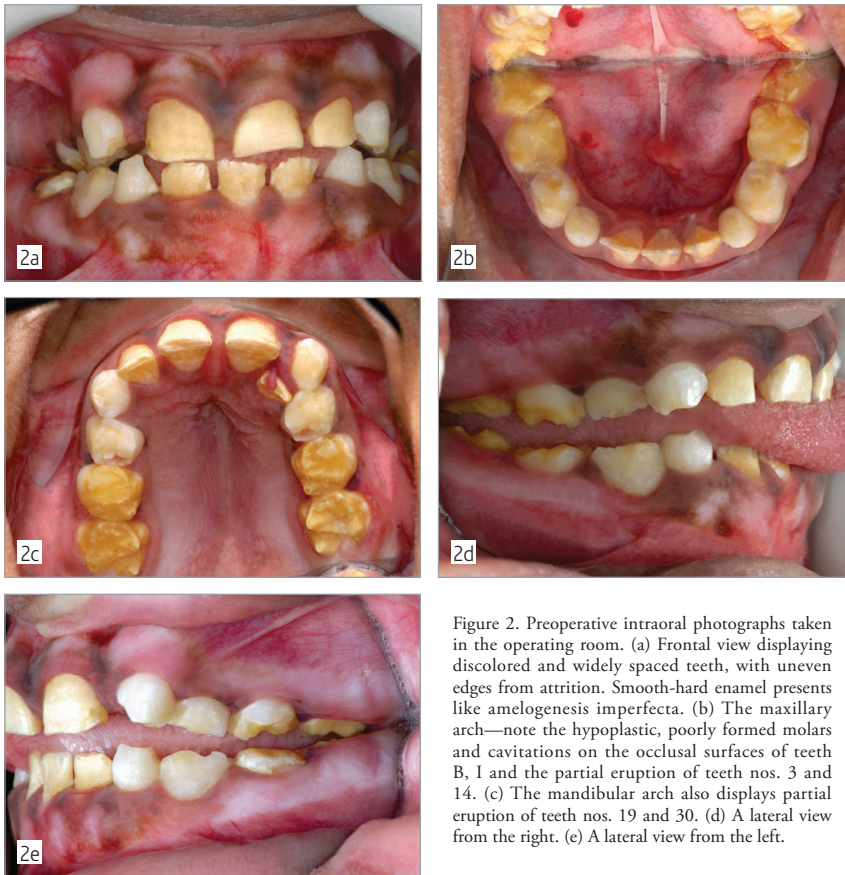


Figure 2. Preoperative intraoral photographs taken in the operating room. (a) Frontal view displaying discolored and widely spaced teeth, with uneven edges from attrition. Smooth-hard enamel presents like amelogenesis imperfecta. (b) The maxillary arch—note the hypoplastic, poorly formed molars and cavitations on the occlusal surfaces of teeth B, I and the partial eruption of teeth nos. 3 and 14. (c) The mandibular arch also displays partial eruption of teeth nos. 19 and 30. (d) A lateral view from the right. (e) A lateral view from the left.

in the CSF, neuromotor defects and cerebellar ataxia.⁷ Many children present in the newborn period with hypotonia, seizures, and myelin degeneration.⁸ Hepatomegaly is characteristic within the first year of life, and neonatal jaundice and nonspecific biochemical disorders of the liver also been reported. Liver changes can progress from fibrosis to cirrhosis over the course a few months time without widespread inflammatory disease or necrosis. In older children, however, liver function may stabilize.⁹ Patients may develop myelin degeneration in the central nervous system, begin to lose previously acquired skills, and develop spasticity that may stabilize or progress and be fatal.⁷ Prognosis of IRD patients is generally poor, with death usually occurring in the second or third decade of life.^{1,6}

IRD's genetic basis is characterized by mutations in PEX genes encoding peroxins that either are responsible for the transport of peroxisomal enzymes into the peroxisomes or contribute to peroxisome membrane integrity.⁵

An adult onset form, Refsum disease is similar in pathogenesis to IRD; however, the defect is in a different gene encoding for the metabolic enzyme phytanoyl-CoA hydroxylase and should not be confused with the infantile variant.

Biochemistry. Diagnosis of IRD can be done biochemically through the measurement of plasma very long chain fatty acids (VLCFAs) which include phytanic acid, followed by a full work-up of peroxisome function

in fibroblast studies to confirm the diagnosis if there is a clinical suspicion of IRD.⁴ These specific VLCFAs only accumulate with dietary exposure, as phytanic acid is an exogenous substance. Therefore, phytanic acid levels are normal at birth.⁸ Contributing factors in phytanic acid accumulation include: limited excretory mechanisms restricted to the kidney and skin and an alternative degradation pathway that is limited to 10 mg of phytanic acid per day.¹⁰ The average American diet contains 50 to 100 mg/day of phytanic acid and easily overwhelms the ability to degrade the excess.⁸

Exogenous sources of phytanic acid are found in nature as a precursor, phytol, which is a constituent of chlorophyll—the organelle found in all photosynthetic organisms such as grass and leafy vegetables. Animals that feed on large quantities of grasses consume large amounts of chlorophyll. Once digested, the phytol is converted into phytanic acid. Subsequently human consumption of foodstuffs rich in phytanic acid are derived from grazing animals such as beef, lamb, pork, and some seafood, as well as dairy produced from cows.¹¹ Limiting the amount of phytanic acid in the diet is recommended in Refsum disease (adult onset form); however, no direct benefit has been found for IRD children. Many young IRD patients are, however, restricted to a low

phytanic acid diet. At the moment, the role that phytanic acid plays in physiology is unclear. Toxic effects, however, have been described in isolated mitochondria of neural origin, namely an increase in reactive oxygen species.¹¹ It is known, however, that the buildup of phytanic acid in tissues creates specific clinical manifestations.⁴ Furthermore, depending on the type of genetic mutation in the PEX gene, IRD patients can present with varying degrees of severity.⁵

IRD anomalies in the craniofacial region can include: eye abnormalities, most notably retinitis pigmentosa; neural migration defects; hepatomegaly; micrognathia; and dwarfism.

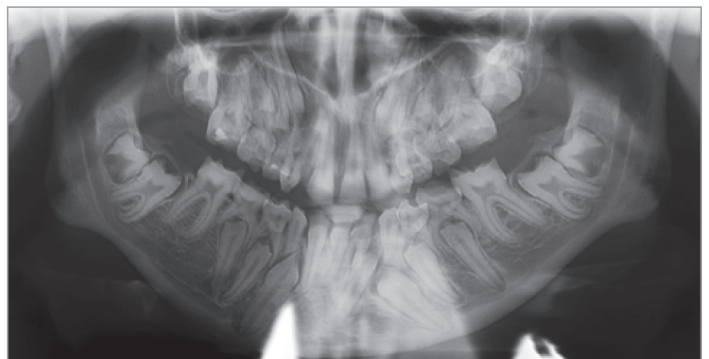


Figure 3. Panoramic radiograph showing multiple impacted permanent teeth, delayed eruption of teeth with nearly complete root development, and ectopic eruption.

Craniofacial features reported include: a high forehead; hypoplastic supraorbital ridges; epicanthal folds; midface hypoplasia; and large anterior fontanelle.⁸ Hypertelorism and broad nasal bridges have also been described in this population.⁵

Dental anomalies have been reported for a group of 3 Amish siblings diagnosed with IRD who all had poorly formed, yellow-orange teeth.¹² Their dental histories are consistent with the findings in this case report, including small, abnormally shaped, and yellow-orange discolored teeth with central diastema.¹² The child's mother confirmed that other children in a support group of parents dealing with IRD have similar dental findings.

Currently there is no literature published in pediatric dentistry related to the dental manifestations and management of IRD patients. The purpose of this paper was to present the clinical manifestations, oral findings, and dental management involving preventive practices, parental education, and the importance of a team approach regarding a child diagnosed with infantile Refsum disease.

Case report. A 15-year-old female diagnosed with IRD presented to the Pediatric Dental Clinic of Cincinnati Children's Hospital Medical Center, Cincinnati, Ohio, for a dental examination (Figure 1). She was referred by a local clinic to address her chief complaint of enamel chipping from her teeth. She had been a patient at the hospital's Pediatric Dental Clinic 6 years ago as a new patient and was admitted to the operating room to extract over-retained primary incisors (D, G, N, O, P, and Q). We had one follow-up visit with her family 6 months after the operating room appointment, and a panoramic film was taken with some difficulty. Based on the findings of delayed dental development, exfoliation of primary teeth, and the hypoplastic enamel noted, the mother was told we would monitor the patient's development and extract the primary molars in the operating room as needed. Other recommendations included future plans to place crowns on the permanent teeth as needed upon eruption. After that appointment, we lost contact with her family until 2009.

The patient's medical history includes: IRD; tight heel cords which were released orthopedically; bilateral short fourth metatarsals; hepatomegaly; sensorineural hearing loss with a cochlear implant in the left ear and a hearing aid in the right; retinitis pigmentosa; nystagmus; and learning delays to the level of a 6- to 7-year-old/second- to third-grade level. Her mother has restricted her diet to exclude items high in fatty acid, beef, and dairy products. The patient was delivered full-term with no complications.

Clinical examination. Her dental history is positive for delayed eruption of her primary dentition. On the day of examination, her mother reported that she did not erupt any primary teeth until approxi-

mately 26-months-old. The patient brushes her teeth in the morning and before bedtime, does not floss, and uses regular fluoride toothpaste. The chief complaint her mother had included concerns that her permanent front teeth were wearing down and that the enamel was chipping off because she grinds her teeth. Her mother reported the presence of

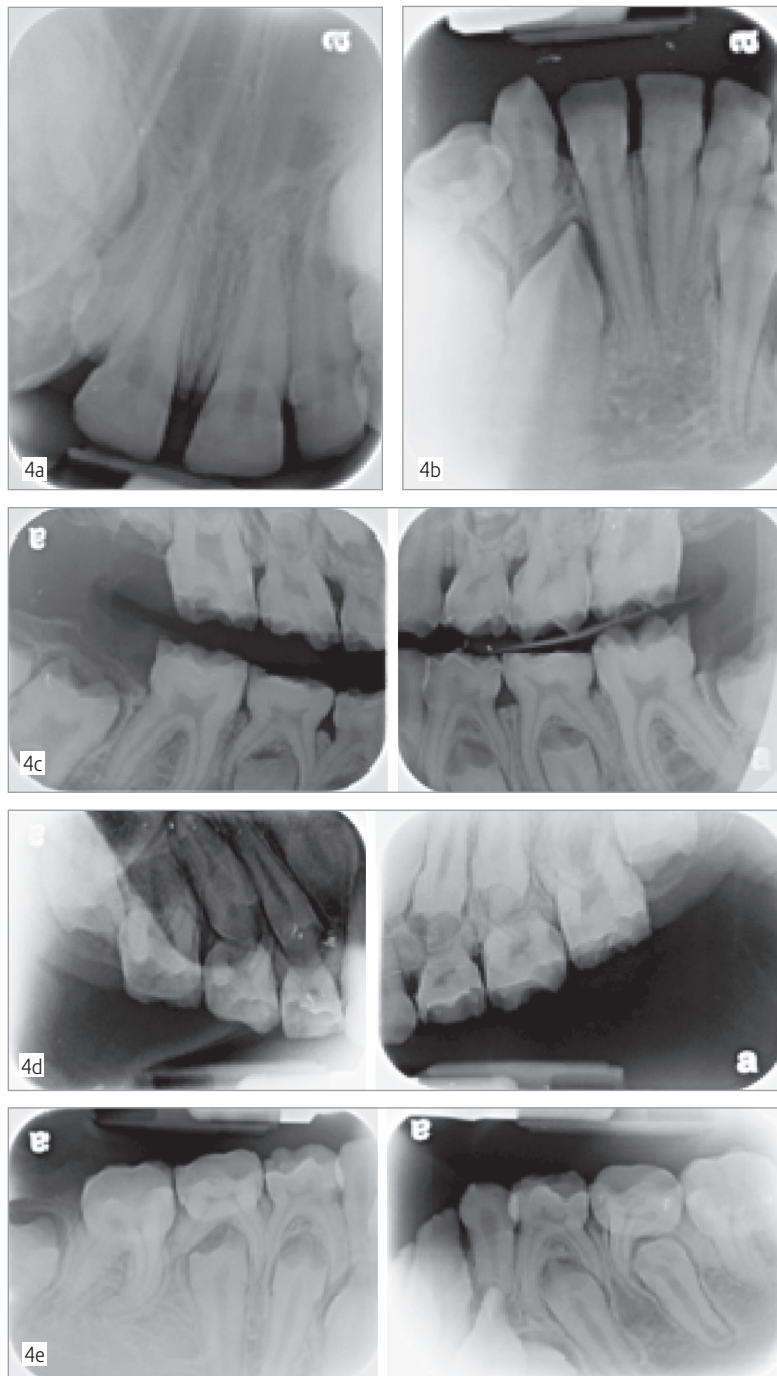


Figure 4. A full-mouth series of radiographs taken in the operating room displays generalized enamel hypoplasia of primary and permanent teeth. (a) Periapical radiograph of the maxillary incisors—note attrition of the incisal edges. (b) Periapical radiograph of the mandibular incisors. (c) Left and right bitewings revealing lack of resorption of the primary teeth. (d) Left and right maxillary posterior periapical radiographs showing partial eruption of the permanent first molars. (e) Left and right mandibular posterior periapical radiographs.

enamel defects congenitally and mentioned that all other IRD children in an IRD support group have the same clinical presentation.

The patient is 148 cm tall and weighs 39.2 kg, placing below the fifth percentile for height and weight for her age. She has a slightly slower and awkward gait, possibly associated with the history of tight heel cords and short metatarsals. She is verbal, but communicates with limited sign language. The patient was cooperative and friendly, often smiling during the examination.

Her craniofacial findings included: low-set ears; mid-face hypoplasia; epicanthal folds; hypoplastic supraorbital ridges; and dry and coarse hair. Her dental findings included: poorly formed enamel; yellow colored teeth; microdontia; widely spaced teeth; chipped enamel from grinding; and generalized attrition from bruxism. Her enamel was not soft or easily pierced with the explorer, and noncarious surfaces were hard but felt rough to the explorer. The dentin underlying the chipped enamel was a dark brown-orange color. Her clinical manifestation was similar to generalized, smooth, hypoplastic amelogenesis imperfecta (AI) (Figures 2a-e). Interestingly, her primary first molars and primary cuspids displayed a smoother surface and less discoloration vs her other affected teeth. Dental development was delayed for her age; the patient has generalized moderate gingivitis, despite good oral hygiene. She has a 50% overbite, 3-mm of overjet, a 4-mm lower midline shift to the left, generalized spacing in the anterior and posterior, and a posterior crossbite. Additionally, she has a convex facial profile and bilateral angle Class II molar relationship. Decay was evident in hypoplastic areas and on the occlusal surfaces of partially erupted molars.

Panoramic radiograph revealed: over-retained primary teeth and multiple impacted teeth (nos. 4, 5, 6, 11, 12, 13, 18, 20, 21, 22, 23, 27, 28, 29, and 31) with nearly complete root development (>75%; Figure 3). Based on the radiographs, an oral surgery and orthodontic consultation was obtained. Both the oral surgeon and orthodontist did not recommend treatment beyond caries control. With the evidence of near complete root development of permanent successors, the eruption potential of succedaneous teeth was limited and orthodontic treatment would be necessary. Subsequently, orthodontic treatment was not recommended due to unpredictable bond strengths and guarded prognosis associated with the enamel's poor quality. Poor patient cooperation and acceptance of orthodontic procedures was another contraindication to providing orthodontic care.

Due to the patient's inability to cooperate, dental care was rendered in the operating room with general anesthesia. The dental restorative procedures provided were consistent with American Academy of Pediatric Dentistry (AAPD) recommendations for restoring teeth with enamel defects. Dental care was focused primarily on conservative caries control in a stepwise manner. Although the patient has generalized enamel hypoplasia, only 3 teeth were carious, with 1 being a permanent tooth (no. 3) that was partially erupted (Figures 4a-e). The plan was to keep the patient on a

strict prevention plan with frequent recall and to provide full coronal coverage once the permanent teeth fully erupted. Stainless steel crowns were not placed on erupted primary teeth because the carious lesions minimally affected the dentin, there was absence of interproximal decay, and, although the teeth were hypoplastic, the enamel was sound.

Caries excavation was conservative and cavity design was extended to enamel that provided resistance to the bur, conventional acid etch with 40% phosphoric acid (Sullivan Schein, Melville, NY), Optibond Solo Plus (Kerr Corporation, Orange, CA.), and lastly Tetric Flow composite (Ivoclar Vivadent AG, Principality of Liechtenstein) as the restorative material. All occlusal surfaces were sealed using Clinpro sealant (3M ESPE, St. Paul, MN). An alternative treatment plan to provide full coverage restorations on the erupted primary teeth was acceptable; however, we elected to be conservative in this case.

A specific preventive plan for the patient was designed. She was given a prescription for Prevident 5000 (Colgate-Palmolive, New York, NY) to use as her primary dentifrice for morning and night brushing due to caries risk in the hypoplastic teeth. We asked that her mother monitor and help with her oral hygiene practices, especially flossing, as her motor control is limited. We encouraged her mother to carefully limit the frequency of snacking and the amount and type of foods and drinks ingested including foods high in refined carbohydrates that are sticky in consistency. We also advised against foods and drinks that are acidic and abrasive due to the risk of losing tooth structure.

To address the chief complaint of wear of the anterior teeth, we discussed the challenges associated with the patient's history of constant bruxism and poor enamel quality that limited the esthetic restorations we could provide. A possible plan included open-faced stainless steel crowns. Her mother was not comfortable with this plan, as her complaint was purely esthetic in nature and the open-faced crowns were not an acceptable esthetic restoration for the mother. The plan was to monitor any pathological effects from grinding and smooth out sharp edges as needed for patient comfort, and the mother was satisfied with this approach. We recommended using of an over-the-counter night guard to prevent further loss of tooth structure from grinding at bedtime. Although she was not sure the patient would accept the appliance, her mother agreed to follow our recommendation.

Discussion

We recommend that pediatric dentists follow AAPD guidelines for the management of generalized enamel defects such as AI. We further recommend early interception, caries prevention, and restoration of affected teeth to prevent attrition based on a patient's caries risk and clinical presentation. Due to the high risk of developing caries, a personalized prevention protocol for the patient should be developed. Frequent recalls are suggested to monitor caries risk as well as growth and development of erupting and exfoliating teeth during the mixed dentition stages. Management of IRD patients should be based on a team approach to include the

patient's pediatrician, pediatric dentist, orthodontist, oral surgeon, and geneticist. We encourage parental education and involvement in this management, and compliance with suggested prevention practices is very important. For IRD patients with cochlear implants, a dental ultrasonic scaler should be used, but electric instruments should be avoided.

Conclusions

Although infantile Refsum disease is a very rare genetic disorder, the specific dental implications as presented in this case report and in the genetics literature warrants discussion and awareness of the management of this particular group of patients. What is striking in this case is that, although the dental findings have not been presented in the dental literature, it is widely known and accepted in the IRD community that dental anomalies are associated with this disease. Pediatric dentists should be aware that IRD patients present with dental anomalies that require frequent recall and thorough parental education regarding dental development, prevention, anticipatory guidance, and an interdisciplinary approach towards management of their child.

The mother of the present study's patient expressed frustrations with dental professionals when she had to explain her child's dental conditions repeatedly at every visit with a new dentist. Therefore, we recommend that dentists stress the importance of having families establish a dental home so that comprehensive and consistent dental care can be provided. Timing the delivery of dental care is extremely important in cases like this where growth and development is unpredictable. When a dental home is established, parent, child, and provider are able to develop and implement specific treatment plans that are customized to patients of this particular disorder.

References

1. Lau CE, et al. Pharmacokinetics and bioavailability of midazolam after intravenous, subcutaneous, intraperitoneal, and oral administration under a chronic food-limited regimen: Relating DRL performance to pharmacokinetics. *Psychopharmacology (Berl)* 1996;126:241-8.
2. Choksi V, et al. Infantile Refsum disease: A case report. *AJNR Am J Neuroradiol* 2003;24:2082-4.
3. NINDS. Infantile Refsum disease information page. Available at: "http://www.ninds.nih.gov/disorders/refsum_infantile.htm".
4. Wanders RJ, Waterham HR. Peroxisomal disorders I: Biochemistry and biogenesis disorders. *Clin Genet* 2005; 67:107-33.
5. Gould SJ, Valle D. Peroxisome biogenesis disorders: Genetics and cell biology. *Trends Genet* 2000;16:340-5.
6. Lazarow PB. Peroxisome structure, function, and biogenesis: Human patients and yeast mutants show strikingly similar defects in peroxisome biogenesis. *J Neuropathol Exp Neurol* 1995;54:720-5.
7. Steinberg SJ, et al. Peroxisome biogenesis disorders. *Biochim Biophys Acta* 2006;1763:1733-48.
8. Krause C, et al. Identification of novel mutations in PEX2, PEX6, PEX10, PEX12, and PEX13 in Zellweger spectrum patients. *Hum Mutat* 2006;27:1157.
9. Gorlin RJ, Cohen MM, Hennekam RCM. Metabolic disorders: Zellweger syndrome (Cerebrohepato-renal syndrome). In: *Syndromes of the Head and Neck*. 4th ed. New York, NY: Oxford University Press; 2001:168-71.
10. Wills AJ, Manning NJ, Reilly MM. Refsum's disease. *QJM* 2001;94:403-6.
11. van den Brink DM, Wanders RJ. Phytanic acid: Production from phytol—Its breakdown and role in human disease. *Cell Mol Life Sci* 2006;63:1752-65.
12. Bader PI, et al. Infantile Refsum disease in four Amish sibs. *Am J Med Genet* 2000;90:110-4.